

## Genotype/Phenotype Analysis of a Photoreceptor-Specific ATP-Binding Cassette Transporter Gene, *ABCR*, in Stargardt Disease

Richard Alan Lewis,<sup>1,2,3,4</sup> Noah F. Shroyer,<sup>4</sup> Nanda Singh,<sup>5</sup> Rando Allikmets,<sup>6</sup> Amy Hutchinson,<sup>6</sup> Yixin Li,<sup>4</sup> James R. Lupski,<sup>3,4</sup> Mark Leppert,<sup>5</sup> and Michael Dean<sup>7</sup>

Departments of <sup>1</sup>Ophthalmology, <sup>2</sup>Medicine, <sup>3</sup>Pediatrics, and <sup>4</sup>Molecular and Human Genetics, Baylor College of Medicine, Houston; <sup>5</sup>Department of Human Genetics, Eccles Institute of Human Genetics, University of Utah, Salt Lake City; <sup>6</sup>Science Applications International Corporation–Frederick, Intramural Research Support Program, and <sup>7</sup>Laboratory of Genomic Diversity, National Cancer Institute, Frederick Cancer Research and Development Center, Frederick, MD

### Summary

Mutation scanning and direct DNA sequencing of all 50 exons of *ABCR* were completed for 150 families segregating recessive Stargardt disease (STGD1). *ABCR* variations were identified in 173 (57%) disease chromosomes, the majority of which represent missense amino acid substitutions. These *ABCR* variants were not found in 220 unaffected control individuals (440 chromosomes) but do cosegregate with the disease in these families with STGD1, and many occur in conserved functional domains. Missense amino acid substitutions located in the amino terminal one-third of the protein appear to be associated with earlier onset of the disease and may represent misfolding alleles. The two most common mutant alleles, G1961E and A1038V, each identified in 16 of 173 disease chromosomes, composed 18.5% of mutations identified. G1961E has been associated previously, at a statistically significant level in the heterozygous state, with age-related macular degeneration (AMD). Clinical evaluation of these 150 families with STGD1 revealed a high frequency of AMD in first- and second-degree relatives. These findings support the hypothesis that compound heterozygous *ABCR* mutations are responsible for STGD1 and that some heterozygous *ABCR* mutations may enhance susceptibility to AMD.

### Introduction

Stargardt disease (STGD; MIM 248200; McKusick 1998) is arguably the most common hereditary recessive macular dystrophy and is characterized by juvenile to young-adult onset, evanescent to rapid central visual impairment, progressive bilateral atrophy of the foveal retinal pigment epithelium (RPE) and neuroepithelium, and the frequent appearance of yellow-orange flecks distributed around the macula and/or the midretinal periphery (Stargardt 1909; Anderson et al. 1995). A clinically similar retinal disorder, fundus flavimaculatus (FFM), often manifests later onset and slower progression (Franceschetti 1963; Hadden and Gass 1976; Noble and Carr 1979). Despite historical nosologic separation (e.g., MIM 230100; McKusick 1992), results of linkage analysis suggested that STGD and FFM were most likely allelic autosomal recessive disorders with slightly different clinical manifestations, caused by mutations of a single gene located within an ~2-cM interval between markers *D1S406* and *D1S236*, at chromosome 1p13-p21 (Kaplan et al. 1993; Anderson et al. 1995; Gerber et al. 1995; Hoyng et al. 1996; Weber et al. 1996).

By a positional candidate approach, the causal gene for recessive STGD (STGD1; MIM 248200) was identified as a photoreceptor-specific ATP-binding cassette (ABC) transporter gene (*ABCR*; GenBank U88667; Genome Database 370748; MIM 601691); mutations segregated appropriately with disease status, in both consanguineous (homozygous) and outbred (compound heterozygous) families with STGD1 (Allikmets et al. 1997b; Gerber et al. 1998; Nasonkin et al. 1998; Rozet et al. 1998). Families with STGD1 showed a high frequency of missense mutations in the *ABCR* gene. In each family with two identified mutant alleles, at least one allele was a missense change or an in-frame deletion, suggesting that most patients with STGD1 may have at least one allele that retains partial function (Allikmets et al. 1997b). Subsequently, a recessive “atypical” phenotype of progressive pigmentary retinopathy with cho-

Received September 4, 1998; accepted for publication December 12, 1998; electronically published February 5, 1999.

Address for correspondence and reprints: Dr. James R. Lupski, Baylor College of Medicine, One Baylor Plaza, 609-E, Houston, TX 77030. E-mail: jlupski@bcm.tmc.edu

© 1999 by The American Society of Human Genetics. All rights reserved. 0002-9297/99/6402-0013\$02.00

roidal atrophy, in a Spanish consanguineous family, was shown, by linkage analysis, to colocalize in the same chromosomal region at 1p13-p21 (Martinez-Mir et al. 1997). Direct sequencing demonstrated a 1-bp deletion in exon 13 of *ABCR* that generated a frameshift early in the coding region and a premature stop codon (Martinez-Mir et al. 1998). Individuals homozygous for this null mutation were predicted to have no functional *ABCR* protein, thus leading to a phenotype more severe than that of STGD. Similarly, homozygosity for a splice-site mutation in intron 30 (IVS30+1G→T) was identified in another consanguineous family and was associated with a severe phenotype of pigmentary retinopathy. Compound heterozygous subjects with a 5' splice-site mutation in intron 40 (IVS40+5G→A) manifested a milder, combined cone and rod dystrophy (Cremers et al. 1998).

Age-related macular degeneration (AMD [ARMD2; MIM 153800]) shares several phenotypic similarities with STGD, including the accumulation of material in and under the RPE (drusen), loss of photoreceptor function, a progressive geographic atrophy of the macular RPE, and occasional disciform macular degeneration (Klein et al. 1978). In a screen for alterations in *ABCR* in a cadre of 167 individuals with isolated AMD, both deletions and putative amino acid substitutions were identified in one allele of *ABCR* in one-sixth (16%) of the sample set (Allikmets et al. 1997a; Dean et al. 1998) but not in a large control group, strongly suggesting a disease association.

The protein product of *ABCR* is expressed only in the retina—specifically, in the rod photoreceptors—and is absent from cone photoreceptors and RPE cells (Allikmets et al. 1997b; Sun and Nathans 1997). Western blotting and immunohistochemistry of macaque, bovine, and mouse retinas showed that *ABCR* encodes rim protein in the rims and incisures of the discs of the rod outer segments, supporting important roles for *ABCR* in either phototransduction or disc structural morphology (Azarian and Travis 1997; Illing et al. 1997; Sun and Nathans 1997). Therefore, different structural alterations in this protein may predispose different phenotypic dystrophic processes, such as no functional protein causing a severe progressive pigmentary retinopathy, compound heterozygotes developing STGD1, or some single-copy mutant alleles predisposing to a late-onset phenotype of AMD.


Interfamilial and intrafamilial variability of clinical phenotype in classic STGD1, manifested either in age at onset or severity of retinal disease, may be influenced by the pairings of mutant alleles. We report here the analysis of *ABCR* mutations in a series of 150 families with STGD1.


## Subjects and Methods

### Family Studies

Of 278 families with STGD/FFM, most of which were of northern or central European ancestry and were ascertained during 1985–98, 150 families were informative for the design and objectives of this study. Pedigrees of 46 of these families were published previously (fig. 1 in the article by Anderson et al. [1995]) and those of the other 104 are shown in figures 1 and 4. Three families, in two of which the parents were first cousins, originated in Saudi Arabia but were from different tribes. All families were ascertained through the Medical Retina and Ocular Genetics Service of the Cullen Eye Institute, Baylor College of Medicine, Houston (by R.A.L.), and by regional, national, and international referral from ophthalmologists, geneticists, and support groups. For each kindred, a detailed family history and pedigree were obtained through personal interviews with appropriate family members. For individuals outside the Houston area, available ophthalmologic, photographic, fluorescein angiographic, electrophysiologic, and psychophysical records were retrieved. The anamnestic and ophthalmologic information for each individual was scored as either affected or normal, by a single observer (R.A.L.) who had no prior knowledge of linkage or mutation data on any family. Each subject or, on behalf of minors or wards, the responsible adult signed a consent for participation in these investigations that was approved by the Baylor Affiliates Review Board for Human Subject Research (Anderson et al. 1995).

The essential and defining features of STGD were (1) pedigrees with at least one living affected individual compatible with autosomal recessive inheritance; (2) an ophthalmoscopically characteristic retinal disorder in families with both parents living; (3) bilateral central visual loss with both “beaten metal” elliptical foveal dystrophy and temporal pallor of the optic discs, documented by retinal color photography, with or without yellow-pigment epithelial flecks in the macular and/or retinal “near periphery”; and (4) the characteristic fluorescein angiographic feature of a dark choroid (Blacharski 1988). The other criteria for characterization of the clinical and angiographic diagnosis of STGD, ascertainment of the families, and methods used for their collection, including for the consanguineous families from Saudi Arabia, are described elsewhere (Anderson et al. 1995; Allikmets et al. 1997b). For comparison, 220 racially matched individuals with no personal history or known family history of STGD served as controls (Anderson et al. 1995; Allikmets et al. 1997b).





**Figure 1** Pedigrees of families segregating STGD. Squares indicate males, circles indicate females, and diamonds indicate sex unknown; a single digit below a symbol indicates the number of individuals. Blackened symbols represent individuals affected with STGD. An asterisk (\*) to the upper left of a symbol indicates an individual affected with AMD. A number sign (#) to the upper left of a symbol indicates an individual affected with retinitis pigmentosa. A diagonal line between a mating pair indicates consanguinity. The family number is given above each pedigree. Specific individuals in a given family are identified by a hyphen and a two-digit number below the symbol. The pedigrees expand the cadre of families reported by Anderson et al. 1995. Eleven families (AR19, AR31, AR59, AR80, AR125, AR129, AR205, AR215, AR218, AR271, and AR324) reported in figure 1 of the article by Anderson et al. [1995] have a family history of AMD.

### Molecular Methods

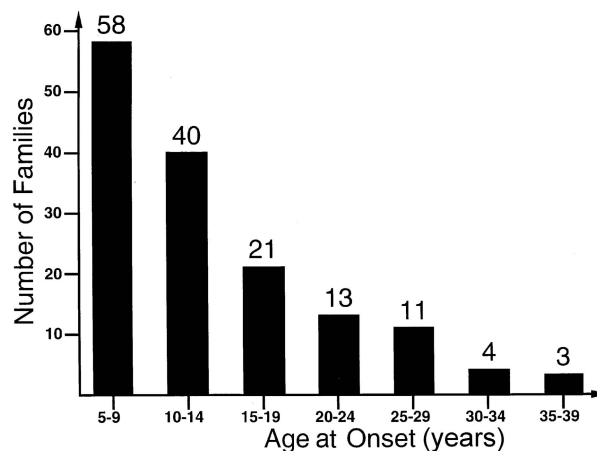
*ABCR* alterations were detected by a strategy of combined SSCP and heteroduplex analyses under optimized conditions, as described elsewhere (Roa et al. 1993; Allikmets et al. 1997b). Sequencing was performed on an ABI sequencer, with both dye-primer and dye-terminator chemistry (Allikmets et al. 1997b). DNA sequencing was performed on each strand, for all exons in which variants were identified by mutation-screening methods.

### Results

#### Clinical Resources

Of the 150 families analyzed by molecular methods (figs. 1 and 4; fig. 1 in Anderson et al. 1995), 78 had one affected individual, 68 included two or more affected siblings, and 6 (AR33, AR279, AR331, AR341, AR375, and AR418) had two generations unequivocally affected with STGD\FFM, without historic evidence for consanguinity. One family, AR289, had a family history of retinitis pigmentosa (MIM 601718). Of those affected, 116 (51%) were males, and 113 (49%) were females. With few exceptions, a concordance in age at onset was noted among affected siblings, regardless of sex, with a tendency toward an earlier age at diagnosis (by 1–2 years) for the second (and subsequent) affected siblings, as would be expected with enhanced parental and physician suspicion after the disorder had been diagnosed in the elder affected sibling. Although initial enrollment emphasized families with classic ages at onset, of 5–19 years (Anderson et al. 1995), other families with later onset of visual symptoms shared identical spectra of progressive loss of visual acuity, ophthalmoscopic abnormalities of the ocular fundus, and angiographic characteristics, including both a dark choroid and the evolution of infiltrative and sequentially atrophic pigment epithelial flecks.

One approach to assess the clinical severity of a pair of mutant alleles was to determine the age at onset of visual impairment, from anamnestic medical records and interviews with selected family members. Among the 278 families with STGD, 406 affected individuals had a mean age at first reported visual loss of  $15.8 \pm 9.6$  years. Of the 150 families with STGD for which the *ABCR* mutation analyses were performed, the mean age at onset was  $15.2 \pm 8.8$  years. We segregated the mean age at reported onset of visual loss by 5-year intervals, beginning at age 5 years (fig. 2). Only two families (AR398 and AR613) reported onset at age 4 years; for simplicity, they were grouped into the youngest half-decade of onset, 5–9 years. Among the several families with affected cousins, the nuclear family identified and enrolled first was scored first. As was expected from the emphasis in our initial recruitment (Anderson et al. 1995), 58 (39%)



**Figure 2** Age at onset of visual impairment in families with STGD. The Y-axis indicates the number of families from the cohort of the 150 families studied for *ABCR* mutations; the X-axis indicates the age at onset, in half-decade increments. The majority of families (119 [~80%] of 150) manifest visual impairment within the first 2 decades of life.

families experienced onset at ages 5–9 years, 40 (27%) at ages 10–14 years, and 21 (14%) at ages 15–19 years. However, 21% of the families in this series had onset at ages  $\geq 20$  years.

Ophthalmoscopic features of the disease, including severity of macular atrophy, extent and density of macular and peripheral flecks, rapidity or severity of involution and atrophy of flecks, and presence of metaplasia of peripheral RPE, could not be readily correlated to age at onset. This correlation was difficult because individuals and families were recruited from throughout North America and from Saudi Arabia and because the requisite photographic and fluorescein angiographic records were not rigorously sequential for individual patients or necessarily contemporaneous with age at onset or at diagnosis. In general, however, the earlier the onset, the more rapid was the loss of central acuity, the more extensive were the areas of atrophy of the foveal RPE, and the more extensive and atrophic were the flecks in the midretinal RPE, depending on the age of the affected individual at the time of retinal photography (Hadden and Gass 1976; Noble and Carr 1979; Armstrong et al. 1998). Similarly, the distribution of the flecks and the extent of atrophy tended to parallel the duration of the disease since onset of symptoms, rather than the age at onset itself.

Four families, AR55, AR290, AR363, and AR534, included two nuclear families related as cousins, with different ages at onset. These families were useful for the analysis of the effect of a single shared mutant allele when paired with a second and different allele, in two limbs of the same kindred. For example, AR55 included

**Table 1****ABCR Mutations in Stargardt Disease**

Exon	Nucleotide Change	Amino Acid Change	No.	Exon	Nucleotide Change	Amino Acid Change	No.	Exon	Nucleotide Change	Amino Acid Change	No.
2	0071G→A	R24H	1	19	2894A→G	N965S	3	36	5196+1G→A	Splice	2
3	0161G→A	C54Y	1	21	3113C→T	A1038V	16		5196+2T→C	Splice	1
	0179C→T	A60V	1	22	3211insGT	FS	1	37	5281del9	PAL1761del	1
	0203C→G	P68R	1		3212C→T	S1071L	1	38	5459G→C	R1820P	1
	0223T→G	C75G	1		3215T→C	V1072A	1	39	5512C→T	H1838Y	1
6	0634C→T	R212C	1		3259G→A	E1087K	1		5527C→T	R1843W	1
	0664del13	FS	1		3322C→T	R1108C	6	40	5585-1G→A	Splice	1
	0746A→G	D249G	1	23	3364G→A	E1122K	1		5657G→A	G1886E	1
8	1007C→G	S336C	1		3385G→T	R1129C	1		5693G→A	R1898H	4
	1018T→G	Y340D	1		3386G→T	R1129L	2		5714+5G→A	Splice	8
11	1411G→A	E471K	1	24	3602T→G	L1201R	1	42	5882G→A	G1961E	16
12	1569T→G	D523E	1	25	3610G→A	D1204N	1		5898+1G→T	Splice	3
	1622T→C	L541P	1	28	4139C→T	P1380L	4	43	5908C→T	L1970F	1
	1715G→A	R572Q	2		4216C→T	H1406Y	1		5929G→A	G1977S	1
	1715G→C	R572P	1		4222T→C	W1408R	4		6005+1G→T	Splice	1
13	1804C→T	R602W	1		4232insTATG	FS	1	44	6079C→T	L2027F	11
	1822T→A	F608I	2		4253+5G→T	Splice	1		6088C→T	R2030X	1
	1917C→A	Y639X	1	29	4297G→A	V1433I	1		6089G→A	R2030Q	1
	1933G→A	D645N	1		4316G→A	G1439D	2		6112C→T	R2038W	1
14	2005delAT	FS	1		4319T→C	F1440S	1	45	6148G→C	V2050L	2
	2090G→A	W697X	1		4346G→A	W1449X	1		6166A→T	K2056X	1
	2160+1G→C	Splice	1	30a	4462T→C	C1488R	2		6229C→T	R2077W	1
16	2453G→A	G818E	1		4457C→T	P1486L	1	46	6286G→A	E2096K	1
	2461T→A	W821R	1	30b	4469G→A	C1490Y	3		6316C→T	R2106C	1
	2536G→C	D846H	1		4539+1G→T	Splice	1	47	6391G→A	E2131K	1
	2552G→C	G851D	1	31	4577C→T	T1526M	7		6415C→T	R2139W	1
17	2588G→C	G863A	11		4594G→A	D1532N	3		6445C→T	R2149X	1
19	2791G→A	V931M	2	35	4947delC	FS	1	48	6543del36	1181del12	1
	2827C→T	R943W	1	36	5041del15	VVAIC1681del	2		6709insG	FS	1
	2884delC	FS	1		5087G→A	S1696N	1				

NOTE.—FS = frameshift.

two (of three) affected siblings (AR55-03 and AR55-07) who had onset of visual loss by age 8 years and whose affected first cousin, once removed (AR55-11), had onset at age 16 years. In AR290, the affected siblings (AR290-06 and AR290-07) each had onset of visual impairment at age 16 years, and their cousin (AR290-10) was affected during her late teens. In family AR534, the proband (AR534-05) experienced impaired vision at age 10 years, and his three first cousins (AR534-10, AR534-11, and AR534-12) had onset of symptoms at ages 8–10 years.

In addition to our observation that single-copy mutations in ABCR were found in ~16% of 167 unrelated and isolated patients with AMD, the self-reported frequency of any form of AMD among parents (age >55 years) and grandparents in 145 of these 150 families was assessed by a telephone or mail poll. Positive responses were evaluated further by recovery and review of clinical records, retinal photographs, and available fluorescein angiograms. Of these 145 families, 31 (21%) reported a positive family history of AMD in the lineage of direct descent to the affected sibship(s). Since most

individuals with early aging features in the retina (dru-sen) are subjectively asymptomatic, this self-reported “prevalence” can be viewed as an underestimate of true ophthalmoscopic prodromal variants, both because ophthalmoscopy often is not performed on asymptomatic individuals and because those with minor findings often are not informed of pathologic abnormalities that do not affect vision.

#### Molecular Analysis

Heteroduplex and SSCP analyses were used to screen the 50 exons (Allikmets et al. 1998; Azarian et al. 1998; Cremers et al. 1998) of ABCR for alterations in the affected proband from each of the 150 families segregating STGD. In 17 exons (table 1), no disease-associated alterations were identified. All 50 exons were screened for variants in 220 unrelated, unaffected control individuals. Any alterations identified in the STGD proband and not identified in the 220 control individuals were evaluated for segregation within the family. In the 150 families with STGD studied, 183 ABCR variations

were identified and considered to be pathologic changes that likely were disease causing (table 1). In families AR33 and AR534, three distinct disease chromosomes were identified; therefore, a total of 302 disease chromosomes were screened. Family AR33 showed a pseudodominant inheritance pattern in which an affected father married an unrelated female carrier; in family AR534, affected first cousins shared a single disease chromosome.

These disease-associated alterations either change the predicted *ABCR* amino acid sequence or likely affect *ABCR* mRNA splicing. They cosegregate with the disease in the pedigrees and were not found in  $\geq 440$  control chromosomes. The common 2588G→C mutation identified in 11 of the 302 disease chromosomes was also found in 2 of 440 control chromosomes; 2453G→A was identified in 1 disease chromosome and in 1 of 440 control chromosomes (Allikmets et al. 1997a; Dean et al. 1998). The 183 STGD1-associated *ABCR* mutations consist of 89 different nucleotide changes, including 80 mutations that, by conceptual translation, affect *ABCR* protein structure, 64 that cause missense amino acid substitutions, 6 that result in nonsense codons, 7 that cause frameshift mutations, and 3 that cause in-frame deletions (table 1). There also were 9 different predicted splice-site mutations. Thirty-four (43%) of the 79 single-nucleotide changes occurred at CpG dinucleotides presumably mediated by deamination of 5-methylcytosine (Coulondre et al. 1978). Of these, 29 are transition mutations, and 5 are transversion mutations.

Two or more mutations were identified in 59 of the 150 families studied. In 10 (7%) families (AR31, AR106, AR128, AR189, AR215, AR254, AR264, AR265, AR285, and AR305), two mutations occurred on a single chromosome, resulting in several complex alleles. In 4 (AR31, AR106, AR128, and AR189) of these 10, a mutation was identified on the second disease chromosome. For the double-mutant chromosomes in the compound heterozygous families (AR31: Y340D and R572Q; AR106: E471K and E2131K; AR128: R572Q and G863A; and AR189: L541P and A1038V) and in those families in which the second disease chromosome was not identified (AR215: H1406Y and V2050L; AR264: D1204N and L2027F; AR254: D249G and R1898H; AR265: G863A and R1898H; AR285: 2714+5G→A and 2884delC; and AR305: G863A and R1898H), in three cases (AR128, AR265, and AR305) each mutation on the double-mutant chromosome had been identified independently as disease causing in other, unrelated families with STGD1 (table 1). In five families (AR31, AR189, AR215, AR254, and AR264) with double-mutant chromosomes, one of the mutations had been identified in other, unrelated families with STGD1. In one family (AR285), a common splice-site mutation was paired on the same chromosome with a frameshift allele.

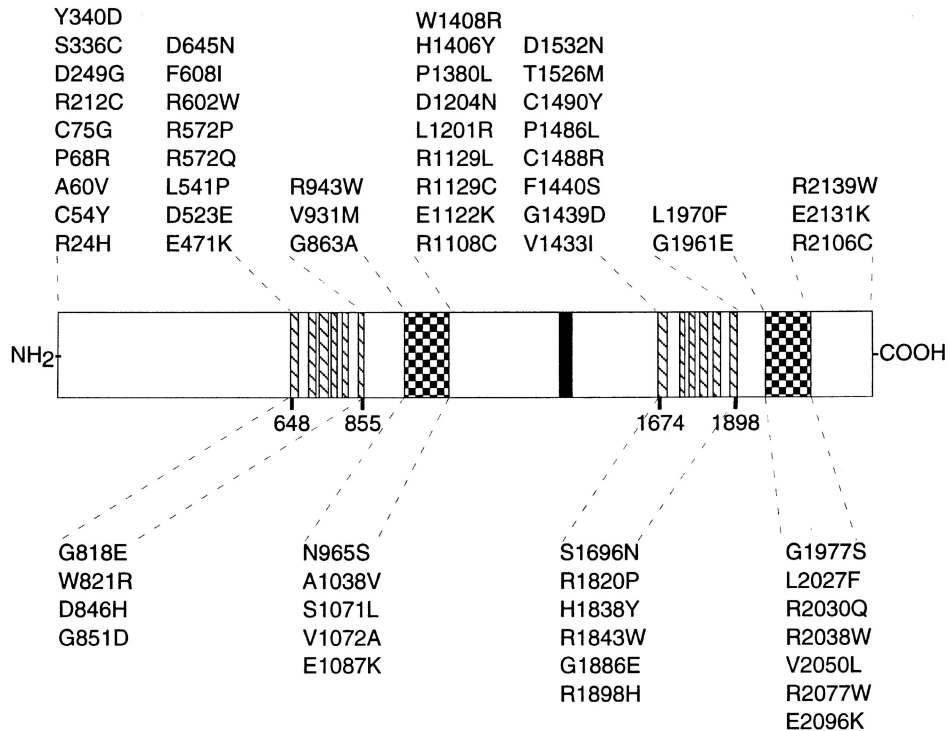
In the remaining family (AR106) with a double-mutant chromosome, neither *ABCR* alteration was identified in other families with STGD1 or in controls, but the double-mutant chromosome segregated with the disease. Thus, mutations were identified on both chromosomes in 53 (35%) of the 150 families studied. Three (AR293, KKESH71, and KKESH214) of these 53 families were identical by descent for polymorphic markers flanking the *ABCR* mutations and had the same mutation (VVAIC1681del, G1439D, and V931M, respectively) segregating on each disease chromosome. The remaining 50 families were compound heterozygotes for *ABCR* mutations.

In 59 families, only one mutation was found by these mutation-screening methods. Thus, mutations were identified on a single disease chromosome, including six double-mutant chromosomes, in 65 (43%) of the 150 families studied. In total, mutations were found in 118 (79%) of the 150 families and in 173 (57%) of the 302 disease chromosomes. Seven mutant alleles, including six missense amino acid substitutions and one splice-site mutation (G863A, A1038V, R1108C, T1526M, G1961E, L2027F, and 5714+5G→A) accounted for 41% of the disease-causing mutations identified in this cohort. In three instances, identical codons were affected by different base-pair substitutions, yielding different predicted missense amino acid substitutions (R572Q and R572P; R1129C and R1129L) or a missense substitution and a stop codon (R2030Q and R2030X). Intriguingly, in each case, these mutations represent a change of a CpG dinucleotide in either the CGA or the CGC codon for the basic amino acid arginine.

Twenty-two of the 64 missense amino acid substitutions occurred in predicted conserved domains of the *ABCR* protein (fig. 3). Predicted conserved domains include 790 amino acid positions, whereas 1,483 amino acids occur in regions not conserved, when compared with other ABC transporters. Therefore, missense mutations in *ABCR* occur with equal frequency in predicted conserved regions (22 [2.8%] of 790) as in regions not conserved (42 [2.8%] of 1,483).

#### *Age-at-Onset Correlations with ABCR Mutations*

In family AR33, the father and the paternal aunt of four patients affected with STGD are also affected with STGD, suggesting a dominant or pseudodominant inheritance pattern (fig. 4). Mutation analysis of *ABCR* and segregation analysis in this family revealed two mutations in each affected individual, which is consistent with recessive inheritance. Interestingly, in family AR33, siblings with identical *ABCR* compound heterozygous mutations are concordant for the half-decade of onset of visual symptoms (fig. 4). These observations suggest that the selected combination of specific *ABCR* mutant



**Figure 3** ABCR missense mutations in conserved domains. Missense mutations are shown on a two-dimensional schema of the ABCR protein. Protein domains were determined by the dense alignment surface transmembrane-prediction program (Cserzo et al. 1997) and by homology to other ABC transporters. Transmembrane domains are shown as diagonally hatched boxes: transmembrane region 1 begins at codon 648 and ends at codon 855; transmembrane region 2 begins at codon 1674 and ends at codon 1898. ATP-binding domains are shown as checkered boxes: domain 1 begins with the Walker A motif at codon 965 and ends with the Walker B motif at codon 1093; domain 2 begins with the Walker A motif at codon 1975 and ends with the Walker B motif at codon 2102. The gray-shaded vertical area represents a conserved hydrophobic domain, the significance of which is not known (Savary et al. 1997). Missense mutations are shown above the diagram, for mutations outside these functional domains, and below the diagram, for mutations within these domains. Twenty-two mutations were identified in the 790 amino acid residues comprising the predicted conserved domains of the ABCR protein, whereas 42 mutations were identified in 1,483 amino acid residues outside these domains. These data demonstrate that missense mutations are distributed evenly across the ABCR protein.

alleles is an important determinant for the age at onset of the disease.

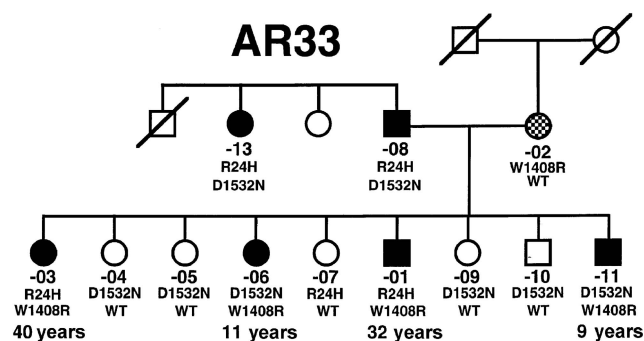
To investigate the hypothesis that the position of mutations in the ABCR protein may be important in determination of age at onset, mutation position (*X*-axis) was graphed and compared with age at onset (*Y*-axis) for the 53 families in which both disease alleles were identified (fig. 5). Individuals AR33-01, AR33-11, AR534-05, and AR534-10 are shown independently because they have different genotypes. Specific ages at onset were assigned according to the earliest onset in a sibship. Pedigrees assigned the same ages at onset were ordered further according to the next earliest onset for a sibling in the family. Families with only one affected individual were placed lower on the *Y*-axis (fig. 5).

Mutations 5' to nucleotide 2588 (codon 863) are rare among individuals with onset at age >14 years (fig. 5). Importantly, putative null mutations, including frameshift and early nonsense mutations, were observed more

frequently in compound heterozygous alleles from patients with onset at age <10 years (5 of 46 vs. 3 of 60; fig. 5). Frameshift mutations in early-onset patients are predicted by conceptual translation to encode an ABCR protein lacking the second transporter domain and, therefore, are likely to be null alleles. Frameshift mutations in later-onset patients are predicted to truncate only the carboxy-terminal tail of ABCR and might retain some transporter function.

To investigate further the relationship between mutation and age at onset, allelic series were constructed for unrelated families that share one specific ABCR mutant allele (allele 1 in table 2). Five series were constructed for mutations present in five or more compound heterozygous families (table 2). Different families with the same combination of alleles (e.g., AR326 and AR391, both with genotype L2027F/T1526M; AR376 and AR393, both with genotype A1038V/R1108C) usually have similar ages at onset, as was shown for





**Figure 4** Pedigree AR33, a family with STGD that manifests a pseudodominant inheritance pattern. Symbols are defined as in the legend to figure 1. The individual represented by the checkered circle had the presence of drusen identified on ophthalmologic examination and subsequently developed disciform macular degeneration. *ABCR* genotypes are given below the symbols. For the compound heterozygous individuals, the age at onset, in years, is given below the genotype. WT = wild type.

the pseudodominant pedigree (AR33) discussed above. However, variation in self-reported age at onset, even by >1 decade, was noted for two families with identical *ABCR* compound heterozygous genotypes (age 8 years for family AR417 and age 20 years for family AR274, each with genotype G1961E/A1038V), suggesting either modifier alleles or environmental factors affecting disease expression or different sensitivity to reported age at onset.

One pedigree, AR534, includes two nuclear families related as cousins, with similar ages at onset; both sets of compound heterozygous *ABCR* alleles were identified. Individual AR534-05, with genotype P1380L/W821R, presented with visual impairment at age 10 years, whereas his cousins, each with genotype P1380L/E1122K, had onset of visual impairment at ages 8–10 years. Two compound heterozygous families, AR335 and AR341, had both mutations in the same exon (F608I/D645N in exon 13 and P1380L/W1408R in exon 28, respectively) and had an early age at onset of 6 years.

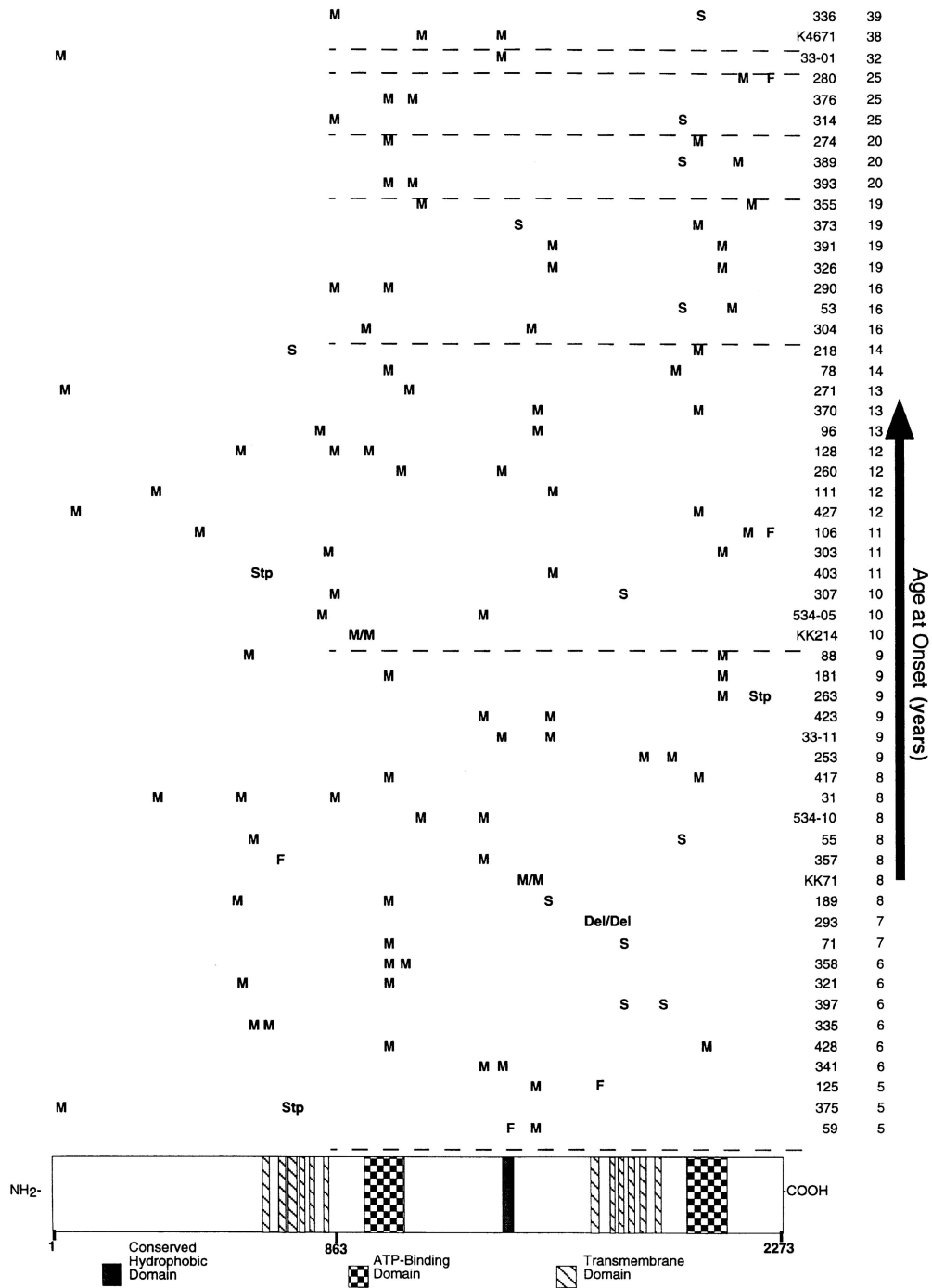
## Discussion

At least five distinct disease phenotypes (retinitis pigmentosa, cone-rod dystrophy, Stargardt macular dystrophy, FFM, and AMD) have been associated with *ABCR* mutations. Alterations in the *ABCR* gene likely are responsible for a substantial amount of retinal pathology. Further information about the clinical manifestations of *ABCR* mutations is essential to the understanding of retinal disease. We have expanded our molecular analysis of *ABCR* by investigating 150 families with STGD for DNA-sequence alterations in the 50 coding exons.

The mutation-screening methods used in this study will not detect large DNA rearrangements or variations in noncoding regions, and the analysis did not include the promoter or regulatory regions. Despite these limitations, we identified a substantial percentage (57%) of mutant chromosomes. Many single-nucleotide changes occur at a known mutation hot spot, a CpG dinucleotide, but they occur at a frequency in *ABCR* that is similar to that observed in other human genes (Cooper and Krawczak 1993). Sixty-four of the 80 nucleotide changes that should affect *ABCR* protein structure cause missense amino acid substitutions. These missense amino acid substitutions occur with equal frequency in predicted conserved regions and those regions not conserved, compared with other human ABC transporter proteins (Allikmets et al. 1995, 1996; Dean and Allikmets 1995). These data emphasize the importance of screening the entire coding sequence of *ABCR* to search for mutant alleles, not merely to search for that portion predicted to encode conserved domains. Ten families have two *ABCR* variants that were found on the same disease chromosome and that were not identified in 220 control individuals, emphasizing the importance of segregation analysis of all *ABCR* variants identified in families with STGD1. The origin and possible mechanism for double-mutant chromosomes or complex alleles are unknown. However, this phenomenon also has been observed at the cystic fibrosis locus, *CFTR* (Zielinski and Tsui 1995). The effect on phenotypic expression of a second mutant allele in a single disease chromosome remains to be determined for a large cadre of such families.

From the 53 families in which both disease chromosomes containing *ABCR* mutations were identified, we have gleaned phenotype/genotype correlations from clinical information on each family. The collective findings suggest that missense mutations in the *ABCR* gene region encoding the amino terminal one-third of the protein are associated with an earlier age at onset (fig. 5). Likewise, frameshift mutations that occur more 5' in the *ABCR* gene usually are associated with an earlier age at onset. Late age-at-onset of the disease is associated with the absence of mutations 5' to codon 863 (nucleotide 2588). In general, identical *ABCR* genotypes manifest similar ages at onset, for symptomatic disease, as exemplified by a pseudodominant family (AR33) with different members having two distinct genotypes (fig. 4).

Considerable variation in the age at onset of visual symptoms in STGD has been noted by many authors. Klein and Krill (1967) reported the range of age at onset, among 27 cases, to be 7–65 years. Hadden and Gass (1976), after excluding anyone of age >60 years, to avoid confusion with AMD, identified a mean age at onset, among 28 patients, of 17 years but a range of 6–45 years. Of 67 patients studied by Noble and Carr (1979), 47



**Figure 5** Age at onset of visual impairment in those families with STGD1 in which both *ABCR* mutant alleles were identified. At the bottom of the figure, the primary sequence of the *ABCR* protein, with conserved functional domains, is shown: the amino terminus is to the left, and the carboxy terminus is to the right. The different combinations of mutant alleles are shown above the *ABCR* protein sequence: M = missense mutation, F = frameshift, Del = deletion, Stp = nonsense-codon mutation, and S = splice-site mutation. In each horizontal row, both mutant alleles are shown for each family with a compound heterozygous *ABCR* mutation. The three families that are homozygous for mutant alleles have a slash between the mutations. The family pedigree number is given to the right (all are “AR” pedigrees, unless otherwise specified), with the age at onset, in years. Horizontal dashed lines indicate half-decades for age at onset.

**Table 2****ABCR Allelic Series**

MUTATION(S)		PEDIGREE	AGE AT ONSET (YEARS)	MEAN AGE AT ONSET ± SD (YEARS)
Allele 1	Allele 2			
G863A	Y340D, R772Q	AR31	8	19.6 ± 12.7
	51961G→A	AR307	10	
	A1038V	AR290	16	
	5714+5G→A	AR314	25	
	5898+1G→T	AR336	39	
A1038V	R572P	AR321	6	12.5 ± 6.9
	S1071L	AR358	6	
	L1970F	AR428	6	
	5196+2T→C	AR71	7	
	G1961E	AR417	8	
	L2027F	AR181	9	
	R1898H	AR78	14	
	G863A	AR290	16	
	G1961E	AR274	20	
	R1108C	AR393	20	
	R1108C	AR376	25	
P1380L	W1408R	AR341	6	8.2 ± 1.5
	E1122K	AR534	8	
	2005delAT	AR357	8	
	D1532N	AR423	9	
	W821R	AR534	10	
G1961E	A1038V	AR417	8	14.3 ± 4.5
	C75G	AR427	12	
	C1490Y	AR370	13	
	2160+1G→C	AR218	14	
	4253+5G→T	AR373	19	
	A1038V	AR274	20	
L2027F	R602W	AR88	9	13.0 ± 5.5
	A1038V	AR181	9	
	R2149X	AR263	9	
	T1526M	AR326	19	
	T1526M	AR391	19	

(70%) had onset in the first 2 decades of life, but 11 (16%) had onset in the 3d decade and 6 (9%) in the 4th decade. Among 49 patients, Gelisken and DeLaey (1985) noted onset of visual symptoms at age <15 years in 32 (65%) patients and at age >26 years in 4 (8%) patients. The 41 patients described by Blacharski (1988) had a mean age at onset of 22.5 years but an age range of 5-64 years.

Among the 150 families for which results of mutation analysis are reported here, the mean age at onset of visual symptoms was  $15.2 \pm 8.8$  years. Approximately 80% of families had onset at age <20 years, and 16% had onset in the 3d decade of life and 5% in the 4th decade. Of our total cohort of 278 families with STGD, 10 had onset of symptoms in the 5th decade of life and 3 in the 6th decade. Thus, the distribution in age at onset of visual loss spreads over 5 decades and is wider than that traditionally reported. The observation that combinations of milder ABCR alleles are associated with later ages at onset may suggest overlap with the age range

for the diagnosis of AMD. It also is conceivable that a single mutant ABCR allele that is dysfunctional over many decades would have phenotypic consequences. From this perspective, the association of self-reported family history of AMD in 21% of our cohort of families with STGD1 is higher than expected. This association raises the potential of increased risk of AMD among family members with STGD1 who carry one mutant ABCR allele. However, the prevalence of AMD in the population is quite high, that is, >10% of individuals of age >65 years (Klein et al. 1992). Therefore, a stringent clinical ascertainment of a large cohort of relatives with STGD1, combined with rigorous epidemiologic investigation and statistical analysis, must establish the significance of AMD individuals heterozygous for ABCR mutations, among family members with STGD1.

Nevertheless, we already have identified a statistically significant incidence of heterozygous ABCR variants in two different AMD cohorts (Allikmets et al. 1997b; Dean et al. 1998). We reported previously that three AMD-associated ABCR variants (R1898H, G1961E, and 6519Δ11bp) (Allikmets et al. 1997a) had been identified in families with STGD1 (Allikmets et al. 1997b). Interestingly, four other STGD1-causing ABCR mutations (E471K, R1129L, 5196+1G→A, and L1970F) in these new families were documented previously as AMD-associated ABCR variants (Allikmets et al. 1997a). Importantly, the G1961E allele, identified as one of the two most frequent variants in both the Utah and the Boston cohorts of AMD patients (Allikmets et al. 1997a), was also the most frequently identified ABCR mutant allele in our cohort of 150 families with STGD1. In 6 of the 16 families with STGD1 who had a G1961E disease chromosome, the other mutant allele also was identified; in all 16 cases, G1961E cosegregated with the disease. Thus, G1961E is a pathologic mutation and not a benign variant.

In the absence of a functional assay for ABCR, it is difficult to establish a role in pathogenicity for any individual ABCR variant, particularly missense amino acid substitutions. However, the absence of the variants in a large control population, their confirmed cosegregation with the disease, and their occurrence in conserved functional domains for many of the mutant alleles indicate that these variants cause disease and are not benign. Some missense mutations occur in regions of ABCR not yet assigned functional significance. The fact that these mutations were not found in controls and that they cosegregated with STGD1 suggests that they also are pathologic alterations.

The most completely characterized ABC transporter gene is CFTR. In a summary of over 550 variants, Zielenski and Tsui (1995) demonstrated that the mutations are distributed over the entire gene and are not clustered in the ATP-binding domains or the transmembrane

regions. As with *ABCR*, the number of complex *CFTR* alleles described shows the importance of scanning the entire gene. Many *CFTR* mutants are associated with altered processing of the protein, resulting in retention of *CFTR* in the Golgi apparatus and/or endoplasmic reticulum. Intriguingly, those *ABCR* missense mutations reported here that are located more toward the amino terminus appear to be associated with earlier onset of the disease. These observations are consistent with the possibility that such mutations represent severe-misfolding alleles or that they result in altered processing of the protein. Functional analysis of such mutant alleles is required, to elucidate the consequences of each mutation on protein structure, processing, and function.

In summary, we firmly established a role for *ABCR* in classic STGD1 and further supported the hypothesis that heterozygous *ABCR* alleles represent a dominant susceptibility locus for AMD. Future in vitro functional studies and animal models with selected *ABCR* mutant alleles will delineate the pathophysiologic steps from an *ABCR* mutation to the phenotype of a retinal dystrophy. Such studies likely will amplify the prominent role of this gene in retinal pathology and will determine its role in normal retinal physiology.

## Acknowledgments

Sincere appreciation is extended to the families described in this article, for their willing and continued cooperation in these investigations, and to their attending physicians, who readily shared anamnestic information. The authors gratefully acknowledge the kindness of R. Stevens, E. Fitzpatrick, J. Cavender, and Z. Karcioğlu and the support of the Research Department of the King Khaled Eye Specialist Hospital, Riyadh, for the referral of three consanguineous families. This study was supported, in part, by The Foundation Fighting Blindness, the George Gund Foundation, the Steinbach Fund, and the National Eye Institute (support to R.A.L. and J.R.L.); by Research to Prevent Blindness, Inc. (support to R.A.L.); by the W. M. Keck Foundation and the Tornquist Charitable Trust (support to M.L.); and by grant N01-CO-56000 from the National Cancer Institute, National Institutes of Health (to R.A.). R.A.L. is a Research to Prevent Blindness Senior Scientific Investigator, and N.F.S. is supported by a National Eye Institute, National Institutes of Health, pre-doctoral training grant, at Baylor College of Medicine. Additional support was provided by the Utah Genome Center. The content of this article does not necessarily reflect the view or policies of the Department of Health and Human Services, nor does the mention of trade names, commercial products, or organizations imply endorsement by the U.S. government.

## Electronic-Database Information

Accession numbers and URLs for data in this article are as follows:

GenBank, <http://www.ncbi.nlm.nih.gov/Web/Genbank> (for *ABCR* [U88667])  
 Genome Database, <http://www.gdb.org> (for *ABCR* [370748])  
 Online Mendelian Inheritance in Man (OMIM), <http://www.ncbi.nlm.nih.gov/Omim> (for STGD and STGD1 [MIM 248200], *ABCR* [MIM 601691], ARMD2 [MIM 153800], and retinitis pigmentosa [MIM 601718])

## References

- Allikmets R, Gerrard B, Glavac D, Ravnik-Glavac M, Jenkins NA, Gilbert DJ, Copeland NG, et al (1995) Characterization and mapping of three new mammalian ATP-binding transporter genes from an EST database. *Mamm Genome* 6: 114–117
- Allikmets R, Gerrard B, Hutchinson A, Dean M (1996) Characterization of the human ABC superfamily: isolation and mapping of 21 new genes using the Expressed Sequence Tags database. *Hum Mol Genet* 5:1649–1655
- Allikmets R, Shroyer NF, Singh N, Seddon JM, Lewis RA, Bernstein P, Peiffer A, et al (1997a) Mutation of the Stargardt disease gene (*ABCR*) in age-related macular degeneration. *Science* 277:1805–1807
- Allikmets R, Singh N, Sun H, Shroyer NF, Hutchinson A, Chidambaram A, Gerrard B, et al (1997b) A photoreceptor cell-specific ATP-binding transporter gene (*ABCR*) is mutated in recessive Stargardt macular dystrophy. *Nat Genet* 15:236–246 (Correction [1977] *Nat Genet* 17:122)
- Allikmets R, Wasserman WW, Hutchinson A, Smallwood P, Nathans J, Rogan PK, Schneider TD, et al (1998) Organization of the *ABCR* gene: analysis of promoter and splice junction sequences. *Gene* 215:111–122
- Anderson KL, Baird L, Lewis RA, Chinault AC, Otterud B, Leppert M, Lupski JR (1995) A YAC contig encompassing the recessive Stargardt disease gene (*STGD*) on chromosome 1p. *Am J Hum Genet* 57:1351–1363
- Armstrong JD, Meyer D, Xu S, Elfervig JL (1998) Long-term follow-up of Stargardt's disease and fundus flavimaculatus. *Ophthalmology* 105:448–458
- Azarian SM, Megarity CF, Weng J, Horvath DH, Travis GH (1998) The human photoreceptor rim protein gene (*ABCR*): genomic structure and primer set information for mutation analysis. *Hum Genet* 102:699–705
- Azarian SM, Travis GH (1997) The photoreceptor rim protein is an ABC transporter encoded by the gene for recessive Stargardt's disease (*ABCR*). *FEBS Lett* 409:247–252
- Blacharski PA (1988) Fundus flavimaculatus. In: Newsome DA (ed) *Retinal dystrophies and degenerations*. Raven Press, New York, pp 135–159
- Cooper DN, Krawczak M (1993) *Human gene mutation*. BIOS Scientific, Oxford
- Coulondre C, Miller JH, Farabaugh PJ, Gilbert W (1978) Molecular basis of base substitution hotspots in *Escherichia coli*. *Nature* 274:775–780
- Cremers FPM, van de Pol DJR, van Driel M, den Hollander AI, van Haren FJJ, Knoers NVAM, Tijmes N, et al (1998) Autosomal recessive retinitis pigmentosa and cone-rod dystrophy caused by splice site mutations in the Stargardt's disease gene *ABCR*. *Hum Mol Genet* 7:355–362
- Cserzo M, Wallin E, Simon I, von Heijne G, Elofsson A (1997)

- Prediction of transmembrane  $\alpha$ -helices in prokaryotic membrane proteins: the dense alignment surface method. *Protein Eng* 10:673-676
- Dean M, Allikmets R (1995) Evolution of ATP-binding cassette transporter genes. *Curr Opin Genet Dev* 5:779-785
- Dean M, Allikmets R, Shroyer NF, Lupski JR, Lewis RA, Leppert M, Bernstein PS, et al (1998) *ABCR* gene and age-related macular degeneration. *Science* 279:1107 (full text, <http://www.sciencemag.org/cgi/content/full/279/5354/1107a>)
- Franceschetti A (1963) Über tapeto-retinale Degenerationen im Kindesalter. In: von Sautter H (ed) *Entwicklung und Fortschritt in der Augenheilkunde*. Ferdinand Enke Verlag, Stuttgart, pp 107-120
- Gelissen O, DeLaey JJ (1985) A clinical review of Stargardt's disease and/or fundus flavimaculatus with follow-up. *Int Ophthalmol* 8:225-236
- Gerber S, Rozet J-M, Bonneau D, Souied E, Camuzat A, Dufier J-L, Amalric P, et al (1995) A gene for late-onset fundus flavimaculatus with macular dystrophy maps to chromosome 1p13. *Am J Hum Genet* 56:396-399
- Gerber S, Rozet JM, van de Pol TJR, Hoyng CB, Munnich A, Blankenagel A, Kaplan J, et al (1998) Complete exon-intron structure of the retina-specific ATP binding transporter gene (*ABCR*) allows the identification of novel mutations underlying Stargardt disease. *Genomics* 48:139-142
- Hadden OB, Gass JDM (1976) Fundus flavimaculatus and Stargardt's disease. *Am J Ophthalmol* 82:527-539
- Hoyng CB, Poppelaars F, van de Pol TJR, Kremer H, Pinckers AJLG, Deutman AF, Cremers FPM (1996) Genetic fine mapping of the gene for recessive Stargardt disease. *Hum Genet* 98:500-504
- Illing M, Molday LL, Molday RS (1997) The 220-kDa rim protein of retinal rod outer segments is a member of the ABC transporter superfamily. *J Biol Chem* 272:10303-10310
- Kaplan J, Gerber S, Larget-Piet D, Rozet J-M, Dollfus H, Dufier J-L, Odent S, et al (1993) A gene for Stargardt's disease (fundus flavimaculatus) maps to the short arm of chromosome 1. *Nat Genet* 5:308-311
- Klein BA, Krill AE (1967) Fundus flavimaculatus: clinical, functional and histopathologic observations. *Am J Ophthalmol* 64:3-23
- Klein R, Klein BEK, Linton KLP (1992) Prevalence of age-related maculopathy: the Beaver Dam eye study. *Ophthalmology* 99:933-943
- Klein R, Lewis RA, Myers SM, Myers FL (1978) Subretinal neovascularization associated with fundus flavimaculatus. *Arch Ophthalmol* 96:2054-2057
- Martinez-Mir A, Bayes M, Vilageliu L, Grinberg D, Ayuso C, del Rio T, Garcia-Sandoval B, et al (1997) A new locus for autosomal recessive retinitis pigmentosa (RP19) maps to 1p13-1p21. *Genomics* 40:142-146
- Martinez-Mir A, Paloma E, Allikmets R, Ayuso C, del Rio T, Dean M, Vilageliu L, et al (1998) Retinitis pigmentosa caused by a homozygous mutation in the Stargardt disease gene *ABCR*. *Nat Genet* 18:11-12
- McKusick VA (1992) *Mendelian inheritance in man: catalogs of autosomal dominant, autosomal recessive, and X-linked phenotypes*, 10th ed. Johns Hopkins University Press, Baltimore
- (1998) *Mendelian inheritance in man: a catalog of human genes and genetic diseases*, 12th ed. Johns Hopkins University Press, Baltimore
- Nasonkin I, Illing M, Koehler MR, Schmid M, Molday RS, Weber BHF (1998) Mapping of the rod photoreceptor ABC transporter (*ABCR*) to 1p21-p22.1 and identification of novel mutations in Stargardt's disease. *Hum Genet* 102:21-26
- Noble KG, Carr RE (1979) Stargardt's disease and fundus flavimaculatus. *Arch Ophthalmol* 97:1281-1285
- Roa BB, Garcia CA, Suter U, Kulpa DA, Wise CA, Mueller J, Welcher AA, et al (1993) Charcot-Marie-Tooth disease type 1A: association with a spontaneous point mutation in the *PMP22* gene. *N Engl J Med* 329:96-101
- Rozet J-M, Gerber S, Souied E, Perrault I, Châtelain S, Ghazi I, Leowski C, et al (1998) Spectrum of *ABCR* gene mutations in autosomal recessive macular dystrophies. *Eur J Hum Genet* 6:291-295
- Savary S, Allikmets R, Denizot F, Luciani M-F, Mattei M-G, Dean M, Chimini G (1997) Isolation and chromosomal mapping of a novel ATP-binding cassette transporter conserved in mouse and human. *Genomics* 41:275-278
- Stargardt K (1909) Über familiäre, progressive Degeneration in der Maculagegend des Auges. *Albrecht von Graefes Arch Ophthalmol* 71:534-550
- Sun H, Nathans J (1997) Stargardt's *ABCR* is localized to the disc membrane of retinal rod outer segments. *Nat Genet* 17:15-16
- Weber BHF, Sander S, Kopp C, Walker D, Eckstein A, Wisinger B, Zrenner E, et al (1996) Analysis of 21 Stargardt's disease families confirms a major locus on chromosome 1p with evidence for non-allelic heterogeneity in a minority of cases. *Br J Ophthalmol* 80:745-749
- Zielenski J, Tsui L-C (1995) Cystic fibrosis: genotypic and phenotypic variations. *Annu Rev Genet* 29:777-807